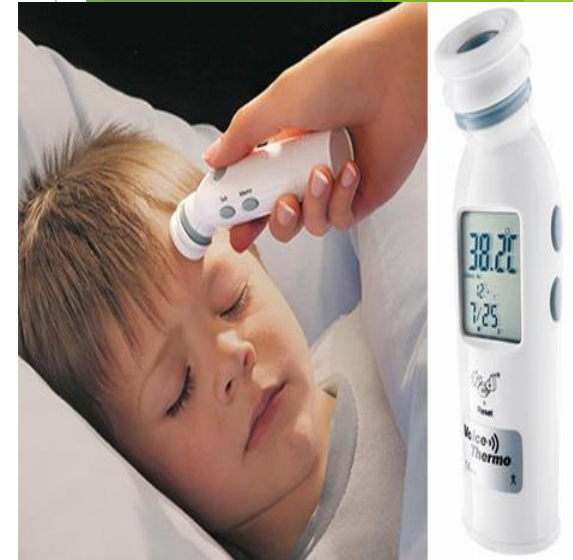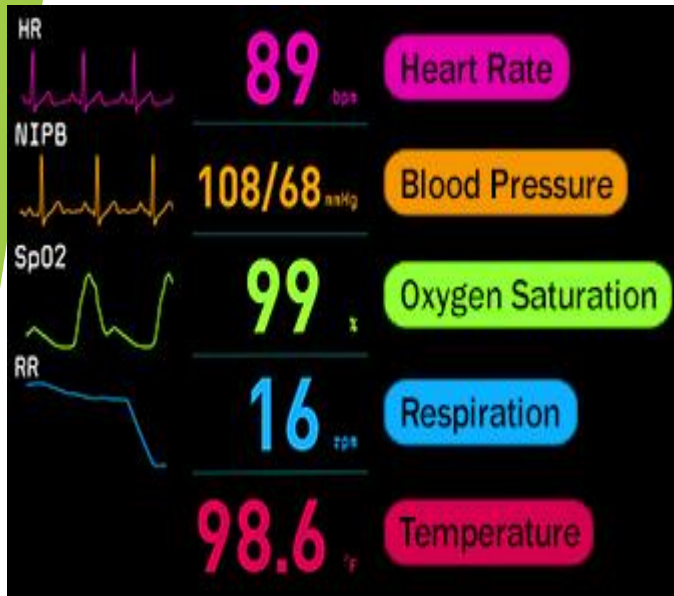


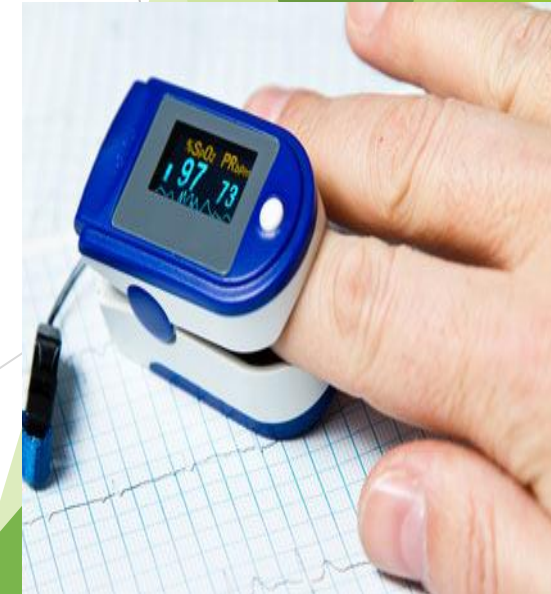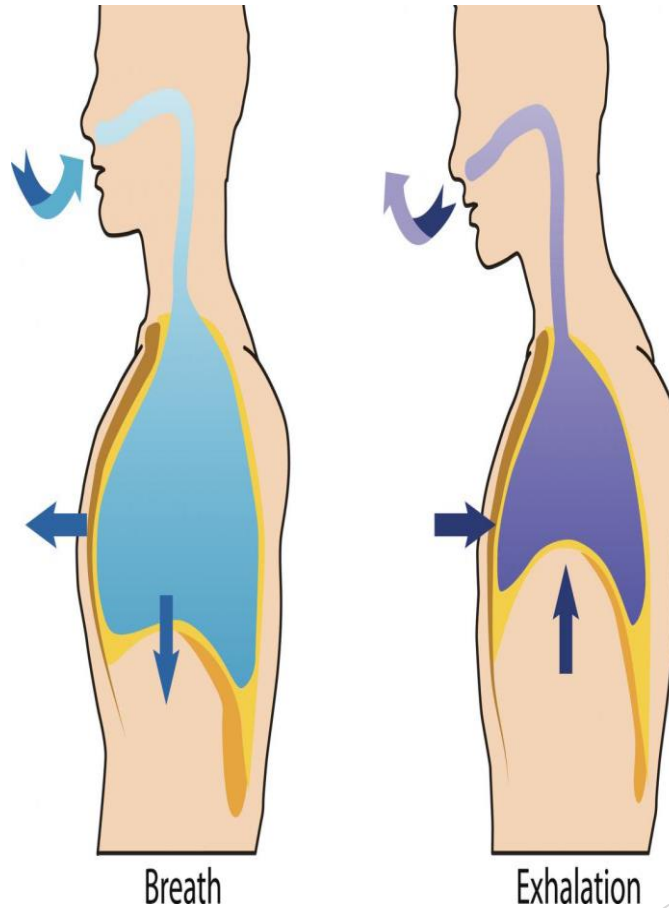
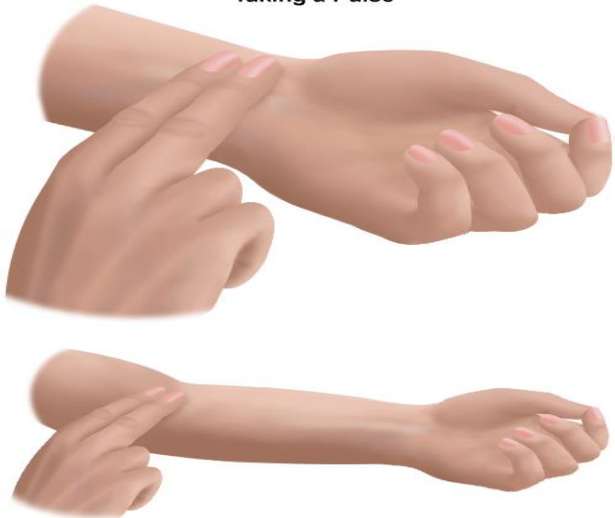FIRST SEMISTER EXPIRMENTS



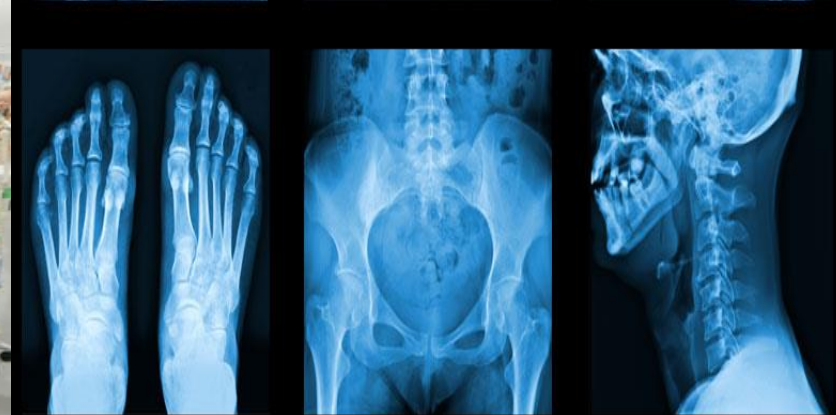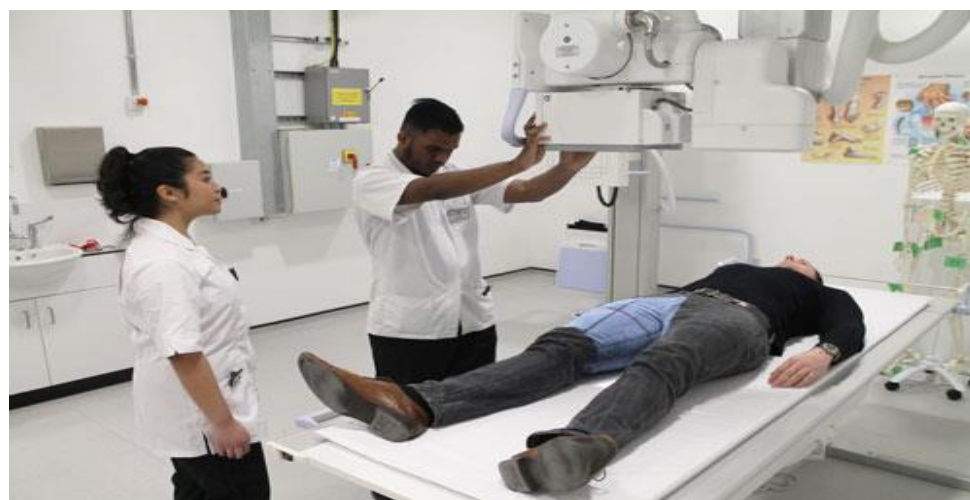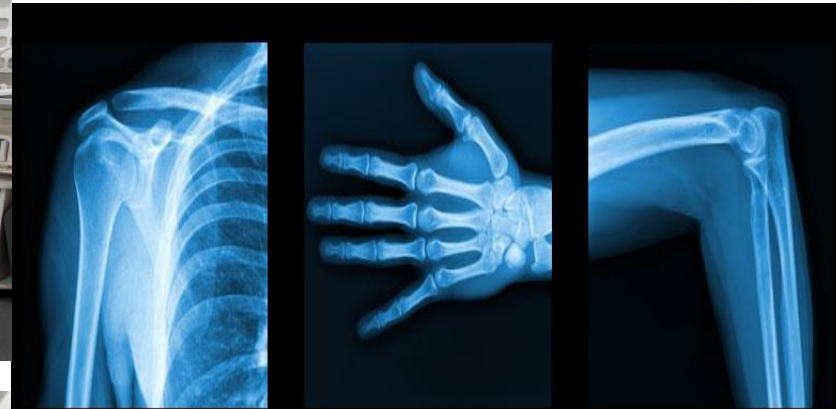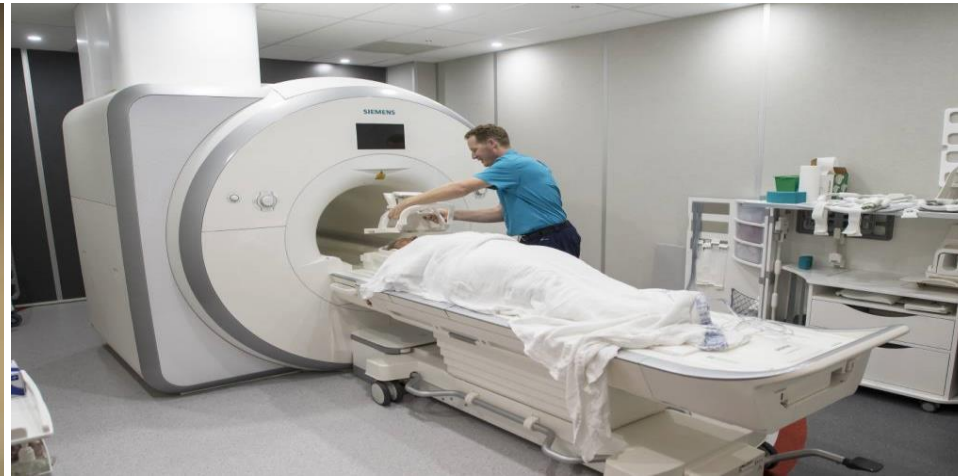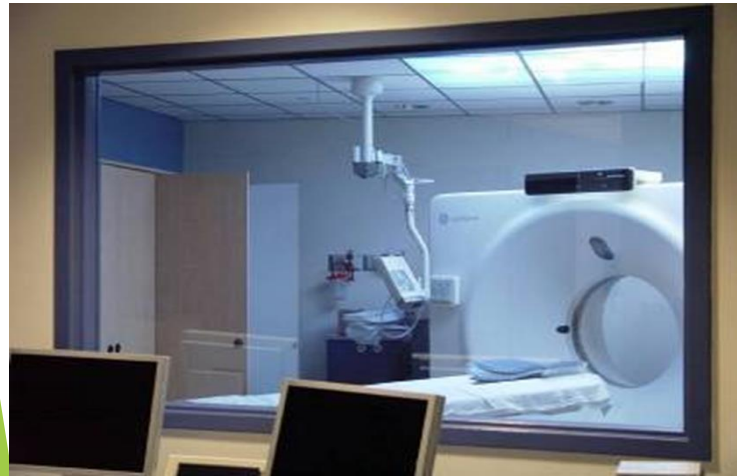1-Vital Signs



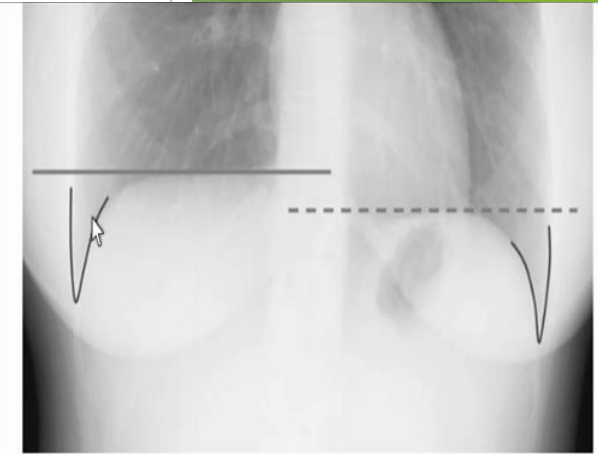
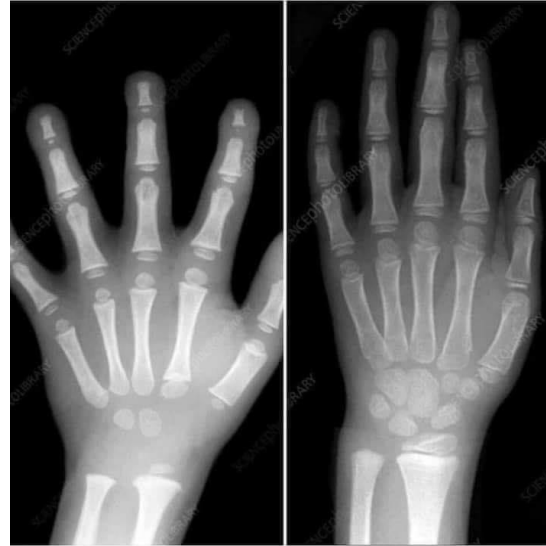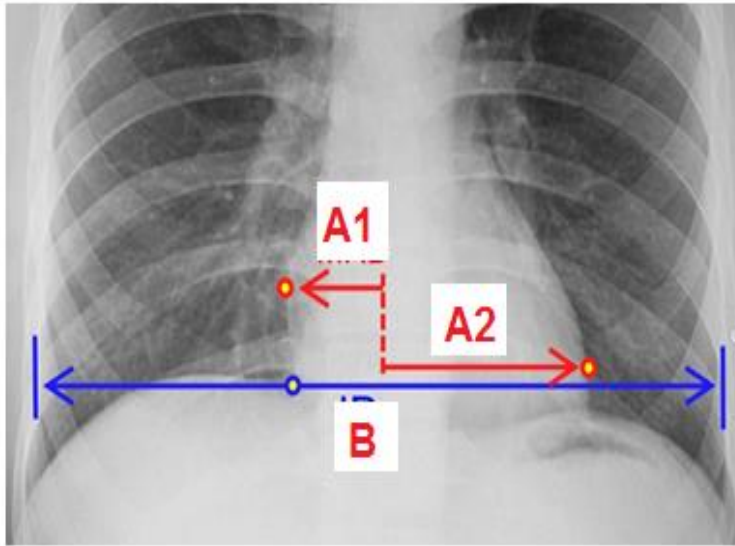
Taking a Pulse



2-Radiographic Technique and Projections



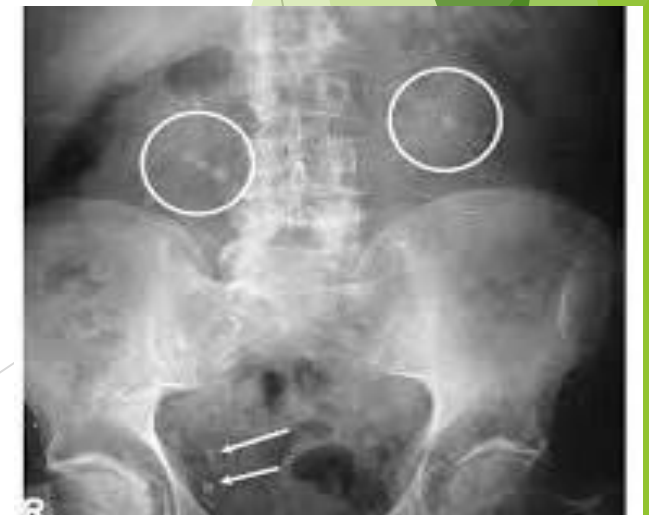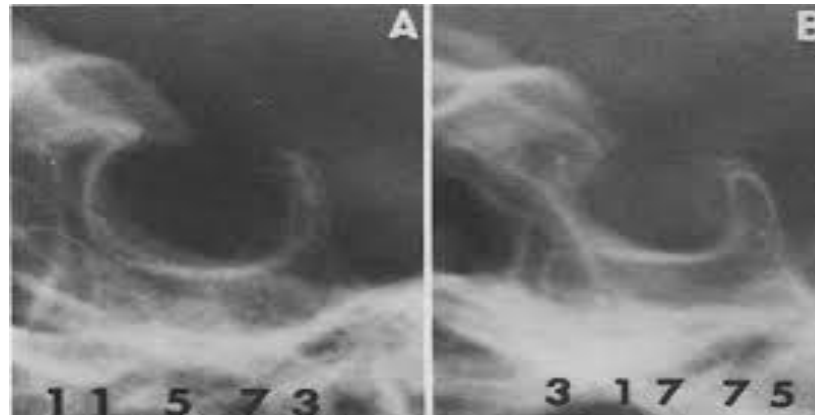
How to Read:- Chest X-ray



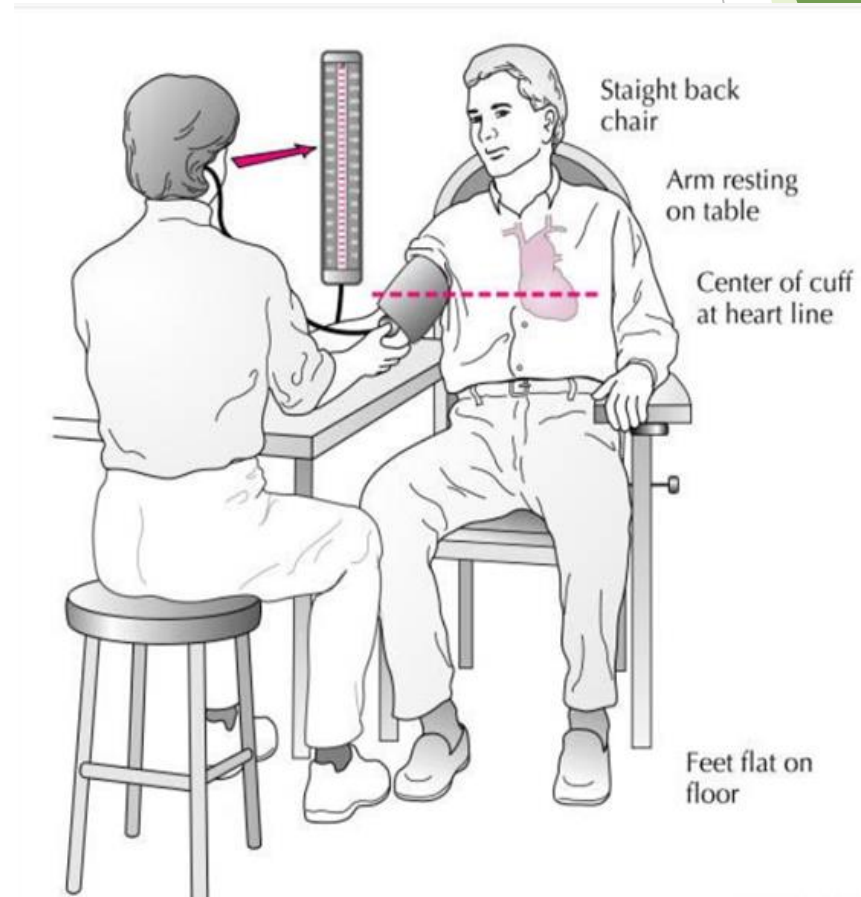
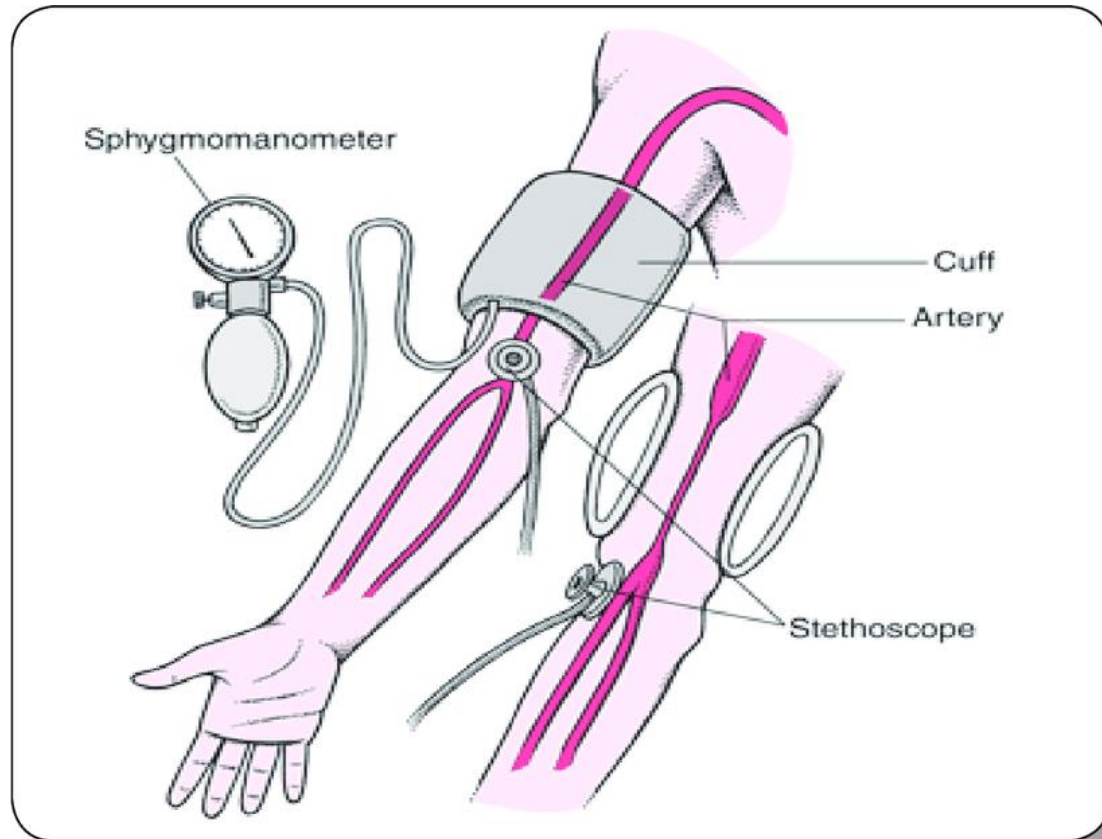
The highest point of the right diaphragm is usually 1-1.5cm (2.5cm sometimes) higher than that of the left

$$\text{Cardiothoracic Ratio} = \frac{\text{Max. horizontal cardiac width}}{\text{Max. horizontal thoracic width}}$$

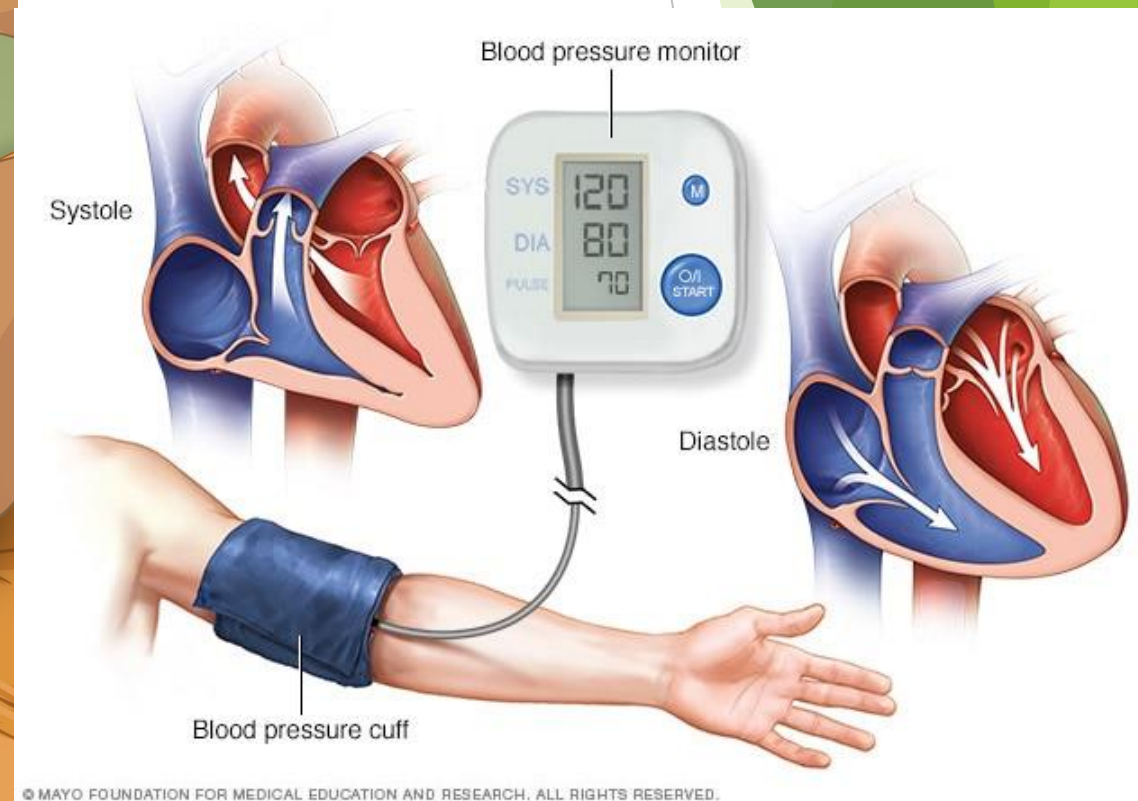
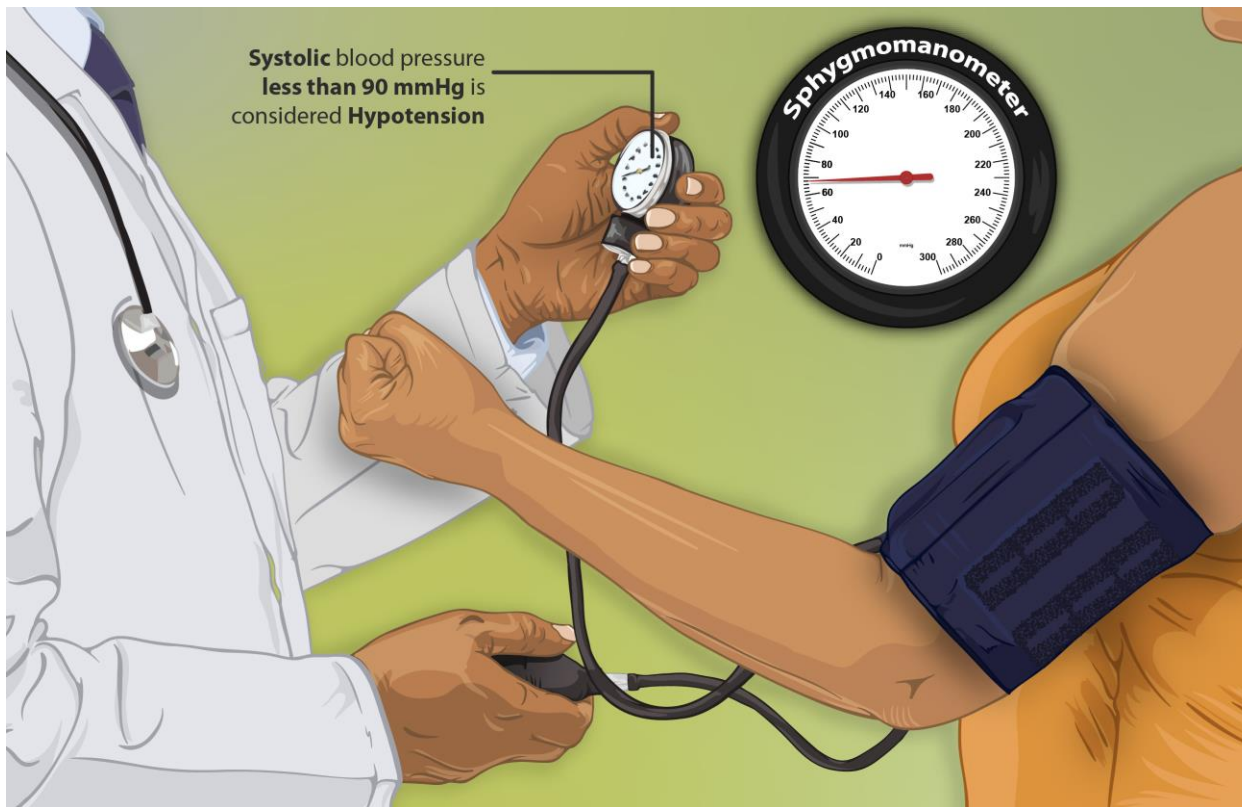
Cardiomegaly is considered to be present if the cardiothoracic ratio > 50% on a PA film.



4-Measurements of Blood Pressure

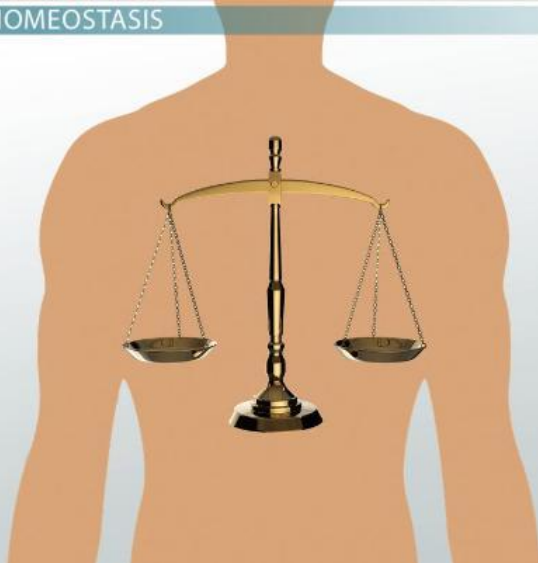


5- Effect Of Posture & Exercise On Blood Pressure

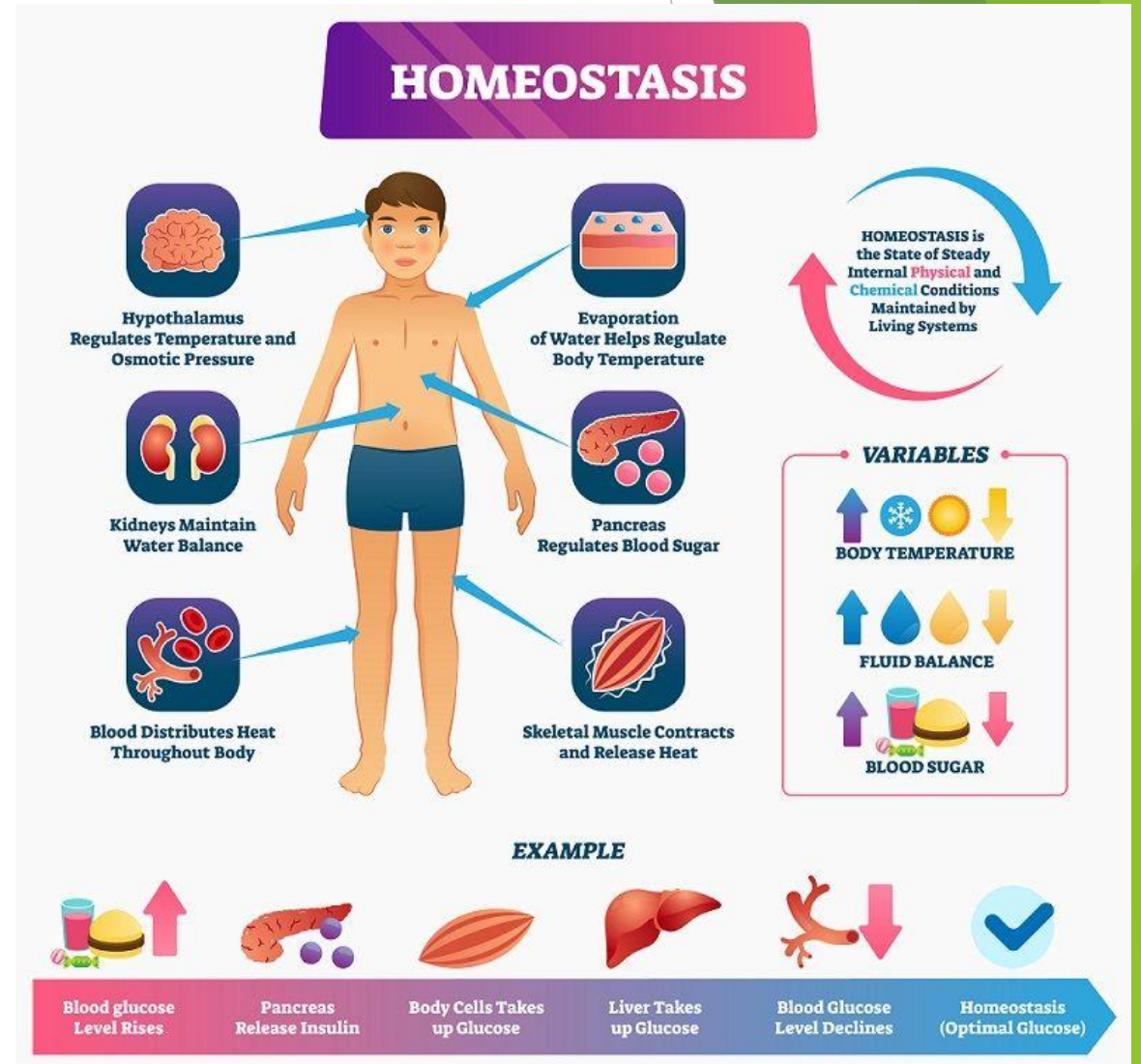


6- Homeostasis

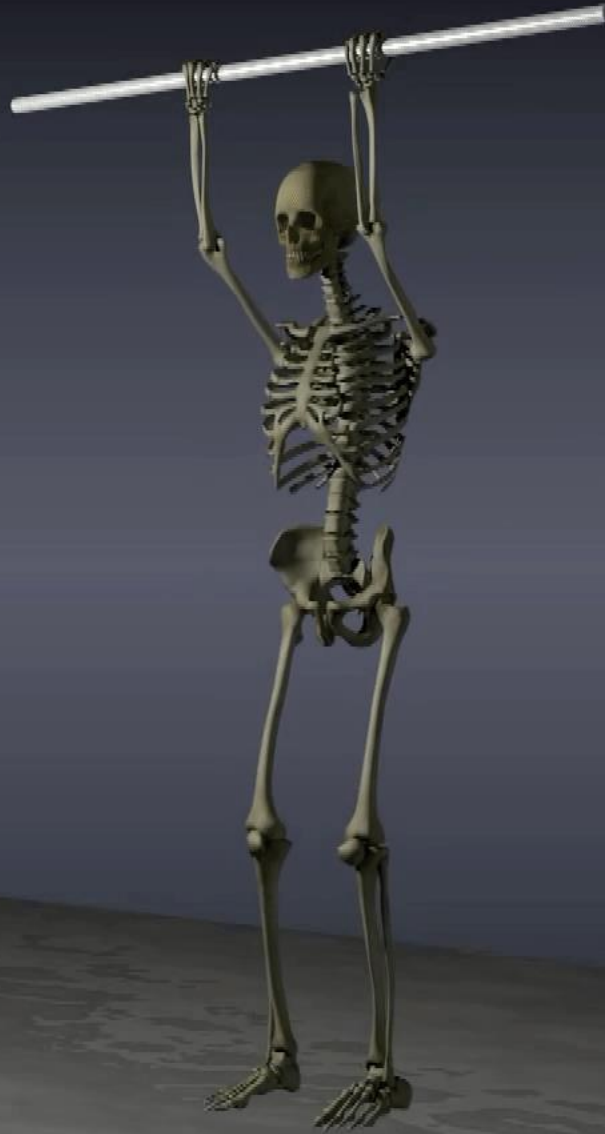DEFINITION OF HOMEOSTASIS



©Study.com



7- Types of Skeletal Muscle Contraction



8- Injection Techniques

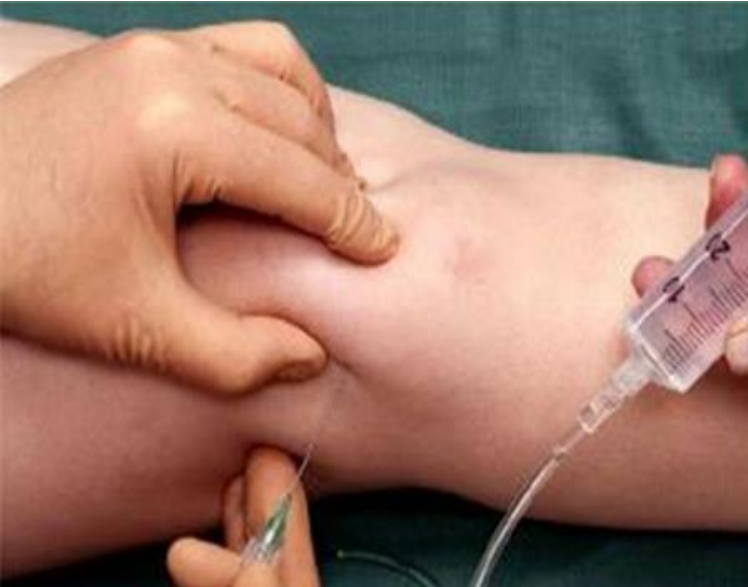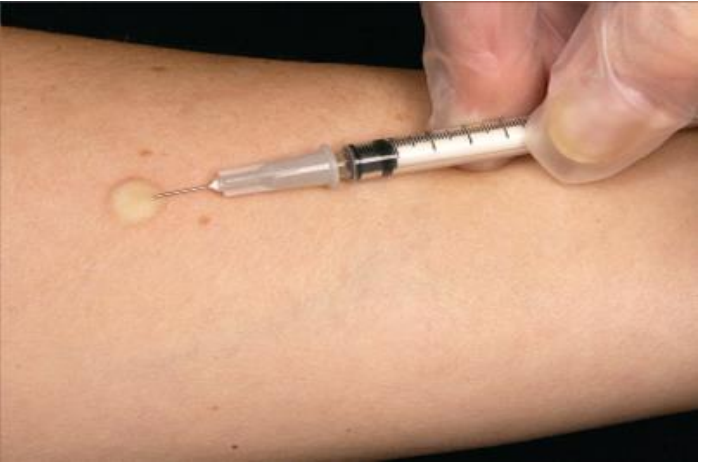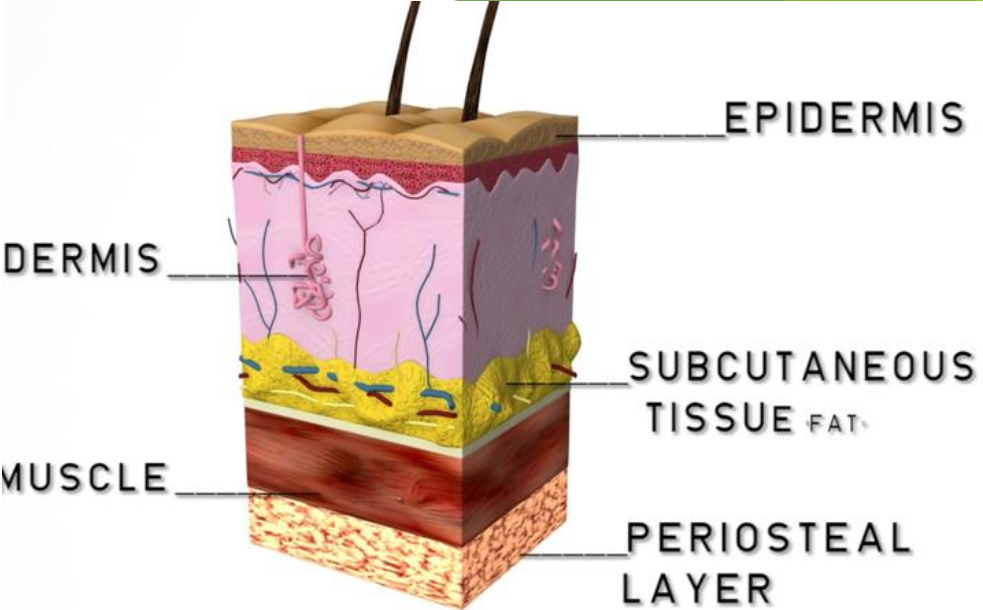
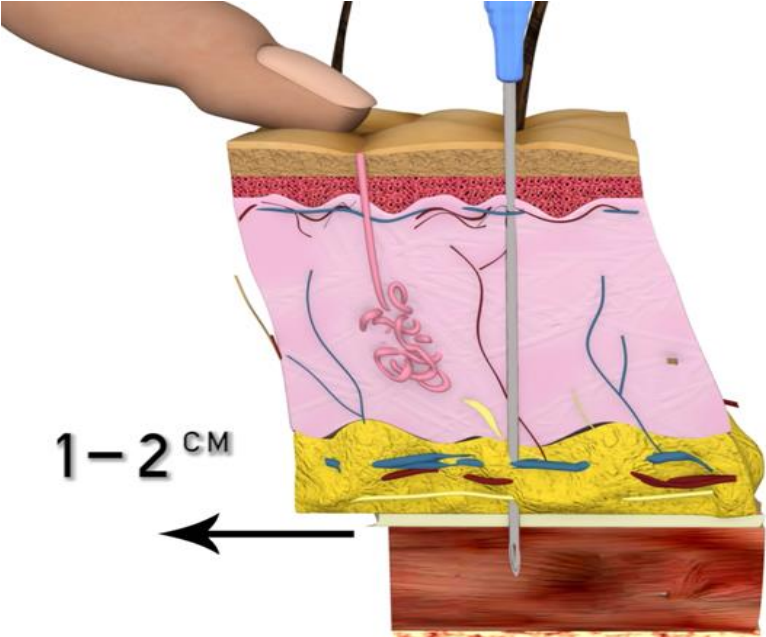


Figure 5. Supraperiosteal Injection

