



زانكۆی سه‌لاحه‌دین - هه‌ولێر
Salahaddin University-Erbil

Comparative anatomical study of the proventriculus in some birds

Research Project

Submitted to the department of biology in partial fulfillment of the
requirements for the degree of **B.A or BSc**. In Biology

By:

Roshna

Supervised by:

Hewa Mohamad Ali

May-2023

بِسْمِ اللَّهِ الرَّحْمَنِ الرَّحِيمِ

((وَمَا أُوتِيتُمْ مِنَ الْعِلْمِ إِلَّا قَلِيلًا))

صدق الله العظيم

سورة الإسراء (٨٥)

Supervisor's Certification

I certify that this thesis was prepared under my supervision at the Department of Biology, College of Education, University of Salahaddin–Erbil and I do here by recommend it to be accepted in partial fulfillment of the requirements for the Bachelor Degree of Science in Biology.

Signature:

Supervisor

Lecture: Hewa Mohamad Ali

Date : / 4 / 2023

Chairman's Certification

In view of the available recommendations I forward this thesis for debate by the examining committee.

Signature:

Asst. Prof. Dr. Saeed Omer Ibrahim

Head of Biology Department

Date : / 4 / 2023

Examination Committee Certification

We certify that we have read this project and as examining committee examined the student (*Roshna*) in its contents and what is related to it and our opinion it meets the standing of a researching project for the bachelor Degree of **Biology**.

Signature:

Name:

Scientific grade:

Date: /4/ 2023

(Chairman)

Signature:

Name:

Scientific grade:

Date: /4/ 2023

(Member)



Signature:

Name: **Hewa Mohamad Ali**

Scientific grade: **lecturer**

Date: /4/ 2023

(Member and Supervisor)

Approved by the Council of the College of Graduate studies

Signature:

Name: **Asst. prof. Dr. Saeed Omer Ibrahim**

Dean of the College of Education

Date: / 4 / 2023

Dedication

I dedicate this research to:

My parents and who taught me that even the largest task can be accomplished if it is done one step at a time,

All whom I appreciate,

Finally, my supervisor Lecturer: Hewa Mohammad Ali

Acknowledgments

I wish to express my thanks to the most gracious "ALLAH", the facilitator in every step of my life and work.

I would like thank to my supervisor **lecturer Hewa Mohamad Ali** for suggesting this topic and giving me useful instructions throughout studying period.

I express my deepest appreciation for Head of Biology Department and this academic staff of Biology Department, College of Education, and University of Salahaddin for their kind assistance and useful advices regarding this research project.

SUMMARY

The current study aimed to investigate the stomach of two species chicken (*Gallus gallus domesticus*) and Guinea Fowl *Numida meleagris* . The experiment was included 6 birds, it is distributed in two equal groups. Ages of birds were average range 6-9 months. The observations was appeared the stomach in both the species, divided into 2 chambers. The results were showed the first stomach is called proventriculus. It's characterized elongated in shape and expansion of the esophagus, located forward the gizzard to posterior at the esophagus in both species. Our study was included some gross findings differentiates in two kinds. However, the proventriculus chicken *Gallus gallus domesticus* was characterized a cylindrical-like and had gastric papillae which it's appeared from external surface of proventriculus with long isthmus. Whereas our results in Guinea Fowl *Numida meleagris*, the glandular stomach was tubular in shape and no protrudes of gastric papillae during outer wall of it with short isthmus. Either gizzard was spherical in shape of chicken and fusiform-like in Guinea Fowls, but it was thin muscular wall and clear at fatty tissue with pale color comparatively with Guinea Fowl, because the starling birds were represented at omnivores depend on the nutrition adding to the grains. In the pigeons, the gizzard had amount of adipose tissue it's covered most the external wall of it. The situation of gizzard in Guinea Fowl was situated posterior toward proventriculus and had thick muscular wall with dark-red in color according to nature of diet, facilities of the grinding grain for indigestion, therefore the Guinea Fowl were considered from granivorous. Also the study was included anatomical statics measurements, length, weight and volume in addition to weights of the birds. Where the study was recorded no significant data mean between species of birds proventriculus and gizzard (table 1).

Key words: comparative, morphology, proventriculus, chicken, Guinea Fowl.

List of Contents

Subject Title	Page No.
Title research	I
Al- ayaat	II
Supervisor's certification	III
Examination committee certification	IV
Dedication	V
Acknowledgments	VI
Summary	VII
List of contents	VIII
Introduction	1-3
Material and Method	4
Result & Discussion	5-8
Conclusions	8
References	8-9

Introduction

The birds species are wide spread around the world. Where they are more than 8000 styles of birds are lived between them (Alexander, 2007). These birds are different from in shape, location and adaptation (Montgomerie et al., 2021). In birds, the process of digestion takes place by mechanical and chemical action on their ingested food material (Karasov and Douglas, 2013). The metabolism of carbohydrates, fats and proteins into the body is closely associated with digestive system (Ogunkoya and Cook, 2009). Digestive system is involved into intake of food, breakdown of consumed food material, convert them into nutrients and finally the absorption of nutrients into blood stream (Nasir et al., 1999). Production of waste from that digested food material and thereby the elimination of it, is also one of the functional aspect of digestive system. In birds, this body system resembling with long tube which seems to be the combo of different organ components that start from beak and ends at vent or cloaca in abdominal region. Bird's gastric apparatus component i.e. stomach is formed by two elements viz. proventriculus and ventriculus or gizzard (Saran et al., 2019). The stomach structure of birds presents assortments that depend on the dietary affinities of each species.

The birds are subdivided into 3 groups according to food nature. First group have soft eating diet as kestrel and owl, second birds have hard eating food such as turkey and sparrow. Either the final group as geese, hoopoe and darter are intermediate between first and second group of the birds, the gizzard function is used in storage and physical digestion in these birds (Abumandour, 2014).

The gizzard is varied among the birds depend on the diet. In vegetarian fowls are marked developed, and considerable masticator function for granivorous and in insectivores (Duke, 1997).

Stomach of birds are not the form of a pouch like the stomach of mammals. The proventriculus is analogous to true stomach in mammals (Abumandour, 2014). the stomach varies considerably in structure in different types of birds, accordingly, as the diet is vegetable or animal (O'Connor, 2019).

The stomach of the birds are divided into two chambers. The first stomach is proventriculus and second chamber is called gizzard or ventriculus. Gizzard stomach is grinding function of grains by the their muscles, so that it's facilities indigestive process.

The two chambers of stomach are different in size and shape depend on nature of birds diet as carnivores, piscivorous and granivorous birds. The glandular stomach (proventriculus) is characterized thin layer base on the food force (grains). Either

ventriculus is called muscular part, which it's crushed the grains in, omnivores, insectivores, granivorous and herbivores(Taylor, 2000).

The stomach of birds is the most active part of the digestive system, located between the oesophagus and the intestine, and it is composed of two distinct parts: a proventriculus (glandular stomach) connected to the esophagus and ventriculus (muscular stomach or gizzard) connected to the duodenum(Kierończyk et al., 2016, Kadhim et al., 2011). The proventriculus is the glandular stomach where hydrochloric acid and digestive enzymes (proteolytic enzymes) are produced and added to the feed and digestion begins. The proventriculus of birds presents variations in the form and mass of stomachs that depend on the dietary habits of each species, being relatively small in graminivores but quite large in carnivores. This part of the stomach is a relatively thick-walled structure (Abumandour, 2014) (Zhang et al., 2016). Hydrochloric acid and pepsinogen are gastric secretions produced in the proventriculus. Pepsinogen is rapidly converted to pepsin by both acid and pepsin already present in the proventriculus(Denbow, 2015). Avian stomach consists of an upper or anterior part, the proventriculus or glandular part and lower part, the gizzard or muscular part (King and McLelland, 1984). Meat-eating bird species have a large and thin-walled stomach, the gizzard in these birds is simple and it produces the compact pellet that is regurgitated complete the digestion. The proventriculus in carnivorous birds are more developed than the gizzard and it is a thick-walled and cone-shaped and take with the gizzard a pear shape with large cavity because of the lacking of the ventricular isthmus (Hamdi et al.,2013 ; Catroxo et al.,1997). In the contrast, seed-eating birds have a thin-walled simple proventriculus and a thick-walled powerful gizzard.

The two parts are connected by the intermediate zone, isthmus (Gelis,2013). These two parts are represented the important portion of enzyme activities (Selvan et al., 2008).

Proventriculus takes the elliptical shape and it secretes the gastric juices (Tadjalli et al.,2011) and propels the juice and food to the main parts of the proteolysis, the gizzard which have the mechanical function of trituration of food (Batah et al.,2012 ; Selvan et al.,2008).

Glandular stomach or true stomach(proventriculus) is lined by glandular mucus membrane which is secreted gastric juices such as pepsin and hydrochloric acid, by this mechanism, the ingested food with its juices passes quickly to the gizzard in which the food particles are reduced to small particles took by the intestine for more digestion and absorption (Saleem,2012).

Ostriches have one of feeding characteristics that they swallow stone and sand or grit to help the gizzard for grinding the food and increase dry matter and then the digestion efficiency (Waugh et al.,2007).

Chemically, gizzard have a keratinize nature lining that termed as keratohyalin or koilin, it was insoluble in keratinolytic solvents and resistant to pepsin (Hodges,1974).

Al-Hamdany(2012) studied the differences of Digestive canal regions in different diet birds. In guinea fowl *Numida meleagris*, proventriculus was a spindle shape muscular tube with thick walls and it begin with small narrow region at the end of oesophagus and expanded gradually at the beginning of gizzard which is, however, took the oval shape and divided into two parts at the distal apex. It lined innerly with horny, yellowish green with parallel, fan shape, scattering folds called koilin, while in Fishers' love bird *Agaporins fischeri* proventriculus was cone shape with inner papillae and the gizzard is disk shaped with three grooves, whereas in common gull *Larus canus*, proventriculus was spindle shape and thicker than the other and the gizzard was pear shaped and elongated(Gelis,2013).

The study aimed to light application of some morphological differences between proventriculus and gizzard of chicken (*Gallus gallus domesticus*) and Guinea Fowl (*Numida meleagris*).

Material and Methods

2.1 Experimental design

This study was carried on adult healthy birds for macroscopical and morphometrical studies. They includes six birds used chicken (*Gallus gallus domesticus*) and Guinea Fowl (*Numida meleagris*) . Ages of birds were included adult age 6-9 months. It was divided into two equal groups, first group was included 3 chicken birds and other group had 3 Guinea Fowl. Then all the birds were sacrificed by dislocated in neck region. The samples were put on dissected board for dissection. We are done mid-line incision through abdomen region so that obtain on viscera. Proventriculus and gizzard were washed by tap water for the cleaning at blood, adhered particle and food for preparation of morphological techniques. The results were included anatomical dimensions. Weights of birds were measured by sensitive electronic balance. The glandular stomach was cut at both junctions with the esophagus and gizzard. So weight and lengths of the widest part of the stomach, its length and weight were calculated (after longitudinal cutting of the stomach and washing in normal saline to remove the content). The lengths were measured by electronic caliper. Either volume was measured by volumetric cylinder. It's contain normal saline, and started to put samples inside it, then we read scaling of volumetric cylinder before and after putting of sample. The images were documented by Optika microscope; model B- 180, and photographed with digital camera (Sony 14.1 MP).

RESULTS&DISCUSSION

The anatomical results showed that the stomach lies in the left median part of the abdominal cavity and occupied most of the abdominal cavity. The stomach in this bird appeared as two chambers structure represented by glandular stomach or proventriculus where the chemical digestion take place and the muscular stomach ,(ventriculus or gizzard) where the mechanical digestion take place.

The size of the gizzard can be changed with the diet nature within the same species, when the bird eaten dry seed in winter, the gizzard being thicker and larger and in contrast in summer when it eat fruits

The esophagus, connecting the proventriculus also known as true stomach. Proventriculus is the glandular stomach where digestion primarily begins. Hydrochloric acid and digestive enzymes, such as pepsin, are added to the feed here and begin to break it down more significantly than the enzymes secreted by the salivary glands. The stones remain in the gizzard until they are ground into pieces small enough to pass to the rest of the digestive tract.

The avian stomach consists of the proventriculus, the intermediate zone, the ventriculus, and the pylorus. The current study included the stomach of chicken (*Gallus gallus domesticus*) and Guinea Fowl (*Numida meleagris*). Generally, the present observations was appeared the stomach in both the species, divided into 2 chambers (figure 1,2,3). This result accepted with (Sherri, 2003)Japanese quail. (Akester, 1986)in domestic fowl *Gallus gallus*. (Rossi et al., 2005)partridge *Rhynchotus rufescens*. Whom said the stomach in some birds, it consisted of three chambers, proventricular, ventriculus and pyloric part.

while (Adam et al., 2022) found the glands to decrease at both extremities. According to (Woods et al., 1993),the glands were located in approximately fifty scattered rows.

Current study was showed the first stomach is called proventriculus. It's characterized elongated in shape and expansion of the esophagus, so it's located forward the gizzard to posterior at the esophagus in both species (figure 1, 2, 3). These findings were corresponding with stated (Tadjalli et al., 2011)in Ostrich [14] In common quail *Coturnix coturnix* and (Salem and A Abdel-Rahman, 2000)in chicken. This part of the stomach was called the fore glandular stomach. These results accepted with(Al-Saffar, 2016) in pigeon *C. livia domestica*. Our study was observed some gross differentiates between two species. However, the proventriculus in chicken *Gallus gallus domesticus* was characterized a cylindrical-like and had gastric papillae which it's appeared from external surface of proventriculus with long isthmus (figure 1a)] .

While our results in Guinea Fowl *Numida meleagris*, the glandular stomach was tubular in shape and no protrudes of gastric papillae during outer wall of it with short isthmus (figure 1b). Either gizzard was spherical in shape during chicken and fusiform-like in Guinea Fowl, but it was thin muscular wall and clear at fatty tissue with pale color comparatively with Guinea Fowl, because the chicken birds were represented at omnivores depend on the nutrition adding to the grains. In the Guinea Fowl, the gizzard had amount of adipose tissue it's covered most the external wall of it (figure 1b,3a). These results were accepted with in Striated Scope Owl *Otus Scors brucei* and goose, turkey, sparrow, kestrel, hoopoe, owl respectively. Whom said the gizzard was fusiform in shape. The study accepted with them about the gizzard surrounded by amount from fatty tissue. Generally, the gizzard in Guinea Fowl was situated posterior toward proventriculus and had thick muscular wall with dark-red in color according to nature of diet, facilities of the grinding grain for indigestion. Therefore the Guinea Fowl were considered at granivorous.. The study was included anatomical measurements, length, weight and volume in addition to weights of the birds. Where the study was recorded no significant data mean between species of birds proventriculus and gizzard (table 1).

In guinea fowl the number of papillae glands (PG) is more than in chicken. The shape of papillae glands (PG) in guinea fowl is larger than chicken (figs. 3a&b).

Table 1: Shows anatomical dimensions of proventriculus and gizzard during two species.

Species	Chicken		Guinea Fowl	
Weight	1500gm		1300gm	
Organs	Proventriculus	gizzard	Proventriculus	gizzard
Length	3.43±01cm	4.54±02cm	4.33±01cm	5.21±01
Width	1.9±04cm	5.8±05cm	2.2±01cm	3.7±02cm
Weight	40.45±03g	60.54±03g	35.65±00g	40.00±03g

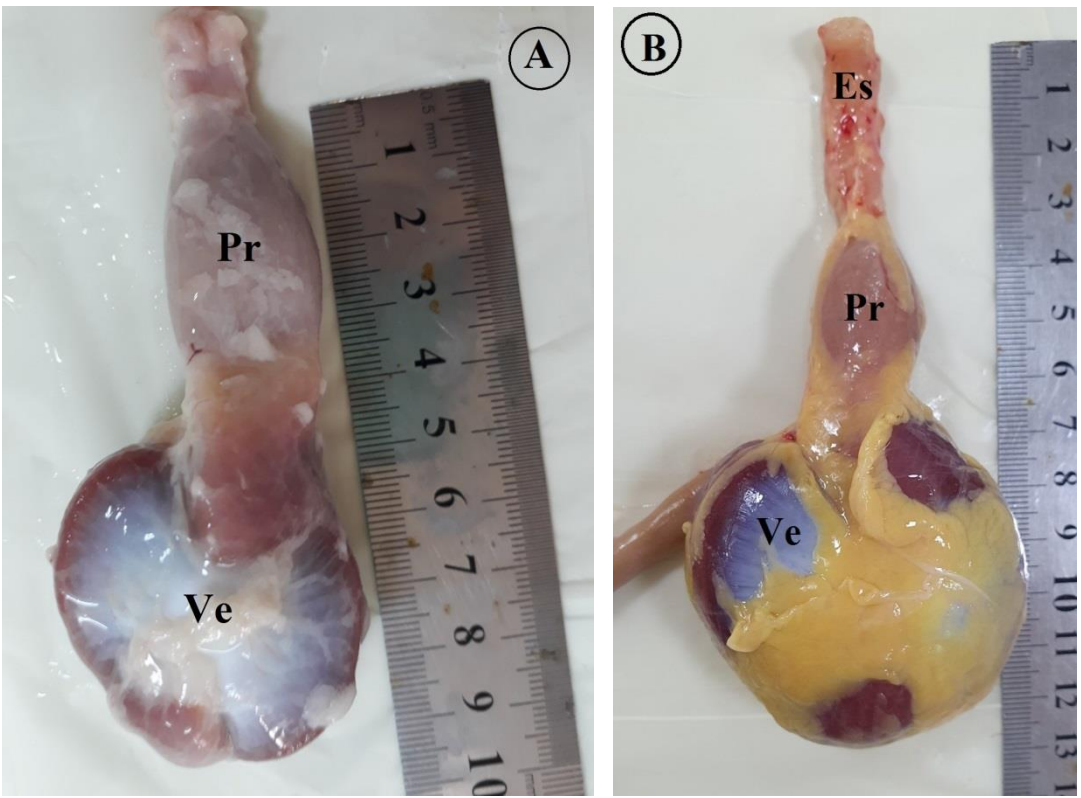


Fig 1: macrophotograph of ventral view showed A., proventriculus (Pr) ventriculus (Ve), in Chicken B. proventriculus (pr), ventriculus (Ve), esophagus (es) and fatty tissue (Ft) in Guinea Fowl.

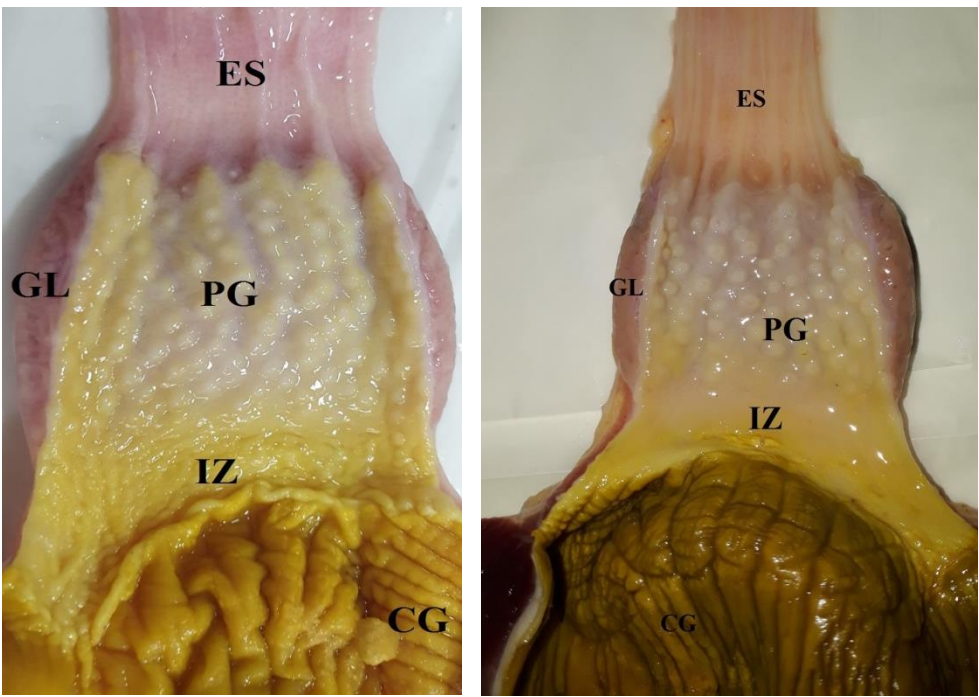


Fig 2: anatomical of shown A. proventriculus (pr), gizzard (gi) (ES) esophagus, (PG) papilla glandularis , (IZ) intermediate zone, (GL) glandular layer in chicken B. proventriculus (pr), gizzard (gi)) (ES) esophagus, (PG) papilla glandularis , (IZ) intermediate zone, (GL) glandular layer) in Guinea fowl.

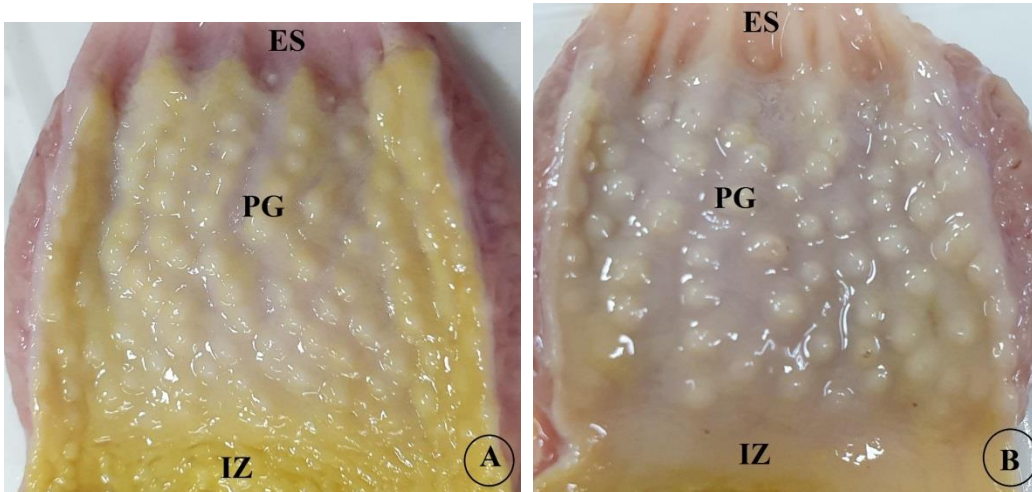


Fig 3: anatomical of shown **A.** proventriculus (ES) esophagus, (PG) papilla glandularis , (IZ) intermediate zone, in chicken **B.** proventriculus (ES) esophagus, (PG) papilla glandularis , (IZ) intermediate zone, in Guinea fowl.

5. Conclusions

The stomach in chicken and Guinea fowl were included two chambers, fore stomach (proventriculus) and muscular stomach (gizzard). In both species, the proventriculus was elongated-like continue with esophagus posteriorly. In starling's proventriculus had appearance of projected processes of gastric papillae in external wall. While in fowl proventriculus has no appear. fowl gizzard was covered by fatty tissue on most external surface of it.

References

- ABUMANDOUR, M. M. 2014. Histomorphological studies on the stomach of Eurasian hobby (Falconinae. *Falco subbuteo*, Linnaeus1758) and its relation with its feeding habits. *Life Science Journal*, 11, 809-819.
- ADAM, M., AJADI, A. A., ATATA, J. A. & AKANBI, O. B. 2011. Traumatic Ventriculitis in an African Ostrich: A Case Report. *Media Kedokteran Hewan*, 33, 48-52.
- AHMED, Y., KAMEL, G. & AHMAD, A. 2011. Histomorphological studies on the stomach of the Japanese quail. *Asian Journal of Poultry Science*, 5, 56-67.
- AKESTER, A. 1986. Structure of the glandular layer and koilin membrane in the gizzard of the adult domestic fowl (*Gallus gallus domesticus*). *Journal of anatomy*, 147, 1.
- AL-SAFFAR, F. 2016. Histomorphological and histochemical study of stomach of domestic pigeon (*Columba livia domestica*). *The Iraqi Journal of Veterinary Medicine*, 40, 89-96.
- ALEXANDER, D. J. 2007. An overview of the epidemiology of avian influenza. *Vaccine*, 25, 5637-5644.
- DENBOW, D. M. 2015. Gastrointestinal anatomy and physiology. *Sturkie's avian physiology*. Elsevier.

- DUKE, G. E. 1997. Gastrointestinal physiology and nutrition in wild birds. *Proceedings of the Nutrition Society*, 56, 1049-1056.
- KADHIM, K., ZUKI, A., NOORDIN, M. & BABJEE, S. 2011. Histomorphology of the stomach, proventriculus and ventriculus of the red jungle fowl. *Anatomia, histologia, embryologia*, 40, 226-233.
- KARASOV, W. H. & DOUGLAS, A. E. 2013. Comparative digestive physiology. *Comprehensive Physiology*, 3, 741.
- KIEROŃCZYK, B., RAWSKI, M., DŁUGOSZ, J., ŚWIĄTKIEWICZ, S & JÓZEFIAK, D. 2016. Avian crop function—a review. *Ann. Anim. Sci*, 16, 653-678.
- MONTGOMERIE, R., HEMMINGS, N., THOMPSON, J. E. & BIRKHEAD, T. R. 2021. The shapes of birds' eggs: Evolutionary constraints and adaptations. *The American Naturalist*, 198, E215-E2. ʻ ʼ
- NASIR, A., MOUDGAL, R. & SINGH, N. 1999. Involvement of corticosterone in food intake, food passage time and in vivo uptake of nutrients in the chicken (*Gallus domesticus*). *British poultry science*, 40, 517-522.
- O'CONNOR, J. K. 2019. The trophic habits of early birds. *Palaeogeography, palaeoclimatology, palaeoecology*, 513, 178-195.
- OGUNKOYA, Y. & COOK, R. 2009. Histomorphology of the proventriculus of three species of Australian passerines: *Lichmera indistincta*, *Zosterops lateralis* and *Poephila guttata*. *Anatomia, Histologia, Embryologia*, 38, 246-253.
- ROSSI, J. R., BARALDI-ARTONI, S. M., OLIVEIRA, D., CRUZ, C. D., FRANZO, V. S. & SAGULA, A. 2005. Morphology of glandular stomach (*Ventriculus glandularis*) and muscular stomach (*Ventriculus muscularis*) of the partridge *Rhynchotus rufescens*. *Ciência Rural*, 35, 1319-1324.
- SALEM, A. & ABDEL-RAHMAN, Y. 2000. Comparative morphometrical and scanning electron microscopical studies on the glandular stomach of the chicken (*Gallus domesticus*), pigeon (*Columbia livia*), duck (*Anas domesticus*) and cattle egret (*Bubulcus ibis*). *Assiut Veterinary Medical Journal*, 44, 35-53.
- SARAN, D., MESHRAM, B., JOSHI, H., SINGH, G. & KUMAR, S. 2019. Gross morphological studies on the digestive system of guinea fowl (*Numida meleagris*). (*International Journal of Livestock Research*, 9, 266-273.
- SHERRI, C. 2003. Avian digestive system. *Holistic bird. News letter. Devoted to health and healing of a vian mind, body, spirit*, 3, 44-53.
- TADJALLI, M., PARTO, P. & SHAHRAKI, A. 2011. Histological study of proventriculus of male adult ostrich. *Global Veterinaria*, 7, 108-112.
- TAYLOR, M. 2000. Anatomy and physiology of the gastrointestinal tract for the avian practitioner. *Birds. Post Grad Found in Vet. Sci. Uni. of Sydney, Aust. Proc*, 334, 107-113.
- WOODS, L. W., LATIMER, K. S., BARR, B. C., NIAGRO, F. D., CAMPAGNOLI, R. P., NORDHAUSEN, R. W. & CASTRO, A. E. 1993. Circovirus-like infection in a pigeon. *Journal of Veterinary Diagnostic Investigation*, 5, 609-612.
- ZHANG, H., GE, T., PENG, S., ZHONG, S & ZHOU, Z. 2016. Microstructure Features of Proventriculus and Ultrastructure of the Gastric Gland Cells in Chinese Taihe Black-bone Silky Fowl (*Gallus gallus domesticus* Brisson). *Anatomia, Histologia, Embryologia*, 45, 1-8.